Intravascular Ultrasound

For decades the only way of directly viewing the coronary arteries was through angiography. As discussed in the section on Cardiac Catheterization, a coronary angiogram is a shadow view of the coronary arteries that serves a dual purpose: diagnosis and treatment -- the continuous fluoroscopic TV image allows the interventional cardiologist to monitor the various wires, balloons and stents, as they are advanced towards the blockages.

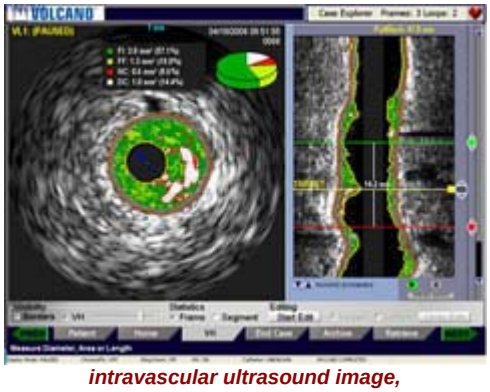

intravascular ultrasound image, courtesy Volcano Corporation

But what if a tiny camera could be mounted on the front of the catheter as it is snaked up the aorta and into the left or right coronary artery? We could see a cross-sectional view of the blockage. Enter IVUS, or intravascular ultrasound. With the invention and refinement of IVUS, it is now possible to thread a miniaturized ultrasound transducer or "camera" into the coronary arteries to give a valuable cross-sectional view from the inside-out, showing the physician where the normal artery wall ends and the plaque begins.

Intravascular ultrasound is only done in the cath lab, and only as part of an angioplasty/stent placement. Some cardiologists use it occasionally, in difficult cases, or to assist in the selection and sizing of stents and balloons.

Others use it routinely, to confirm accurate stent placement and optimal deployment. One of the causes of stent thrombosis or restenosis is poor "stent apposition" -- the stent has not been expanded to the full width of the artery, and this under-expansion creates a "pocket" which can collect platelets and other debris, causing a reblockage. Research conducted using IVUS has confirmed that one of the causes of restenosis is inadequate dilatation; that is, physicians, concerned with injuring or dissecting the artery itself, have tended to "play it safe" and end up undersizing or underinflating the balloon and stent.

A final and very important feature of IVUS is "plaque characterization". Because the ultrasound signal varies, depending on the density of the tissue is it imaging, the data can be displayed in brightness or with colors to show these different layers in the artery. And the plaque inside the artery becomes not just a "blockage", but a specific type of blockage: an older, calcified plaque or a softer unstable or "vulnerable" plaque that is in danger of rupturing.

It is now thought that heart attacks are not necessarily caused by arterial narrowing, as much as by vulnerable plaque rupturing and sending thrombin into the bloodstream, which causes clotting and stoppage of blood flow. If a cardiologist sees an area of vulnerable plaque, he or she can stent it, covering and stabilizing a potentially dangerous area of the arterial wall.

Who Does the Procedure: Intravascular Ultrasound is done during an angioplasty by an interventional cardiologist in the catheterization laboratory with the cath lab team.

Patient Preparation: Since IVUS is seldom performed as a stand-alone imaging procedure, but as part of the angioplasty/stent procedure, no additional preparation is needed: the preparation is the same as for a Cardiac Catheterization.

***** photo courtesy of Toshiba America Medical Systems***